Original Article

Outcome of Post Tuberculous Meningitic Hydrocephalus Following Neurosurgical Intervention

*Lal Rehman**
*Haroon-Ur-Rasheed ***
*A.Sattar Hashmi****
*Mushtaq Ahmad Mian *****

**Assistant Professor,*
*** Postgraduate Resident*
****Professor and head*
*** ****Postgraduate Resident*
Department of Neurosurgery,
Jinnah Post Graduate Medical Centre
Karachi.

Objective: To find out the outcome in terms of mortality in adult patients with post tuberculous meningitic hydrocephalus after neurosurgical intervention.

Design: Descriptive study.

Place and Duration of Study: It was a one year study from April 2007 up to May 2008, conducted in the Department of Neurosurgery, Jinnah Post graduate Medical Centre, Karachi.

Patients and Methods: A total of 42 patients with tuberculous meningitis and hydrocephalus were included in the study. Data collection was done with the help of a proforma including the clinical features, Glasgow coma score (GCS), CT scan findings, surgical intervention and post operative outcome. The patients were divided into two groups as group I with GCS 9-15 and group II with GCS 3-8.

Results: There were total 42 patients with age range from 15 to 60 years. In group I we had 29 patients and in group II there were 13 patients. In group I ventriculoperitoneal (VP) shunt was inserted in 27 patients and external ventricular drain (EVD) was inserted in two patients while in group II VP shunt was inserted in 2 patients while EVD was inserted in 11 patients. Follow up was done for 3 months; all of the patients were put on anti tuberculous treatment (ATT). In group I there were 2 mortalities while in group II, six patients expired. So the overall mortality was 19%.

Conclusion: The outcome of Neurosurgical intervention in patients with post tuberculous meningitic hydrocephalus depends upon the clinical condition and GCS of the patient. In good GCS, early intervention has better results and lower mortality.

Key Words: Tuberculous Meningitis, Hydrocephalus, VP Shunt.

Address for Correspondence:
Dr Lal Rehman,
Assistant Professor,
Department of Neurosurgery,
Jinnah Post Graduate Medical Centre
Karachi

Introduction

Tuberculous meningitis (TBM) is a serious neurological disease with significant morbidity and mortality.[1] Hydrocephalus, a common complication of TBM, which can occur either early or late in the clinical course, as well as either before or after commencement of anti-tuberculous drugs. [2] Hydrocephalus is probably a result of basal adhesive meningeal reaction wherein the flow of the CSF is obliterated in its course from the point of exit from the fourth ventricle to the site of its absorption in the arachnoid villi. [3] Hydrocephalus may be detected at presentation, often presenting as deterioration in conscious level. [4] CT scan and MRI help in the diagnosis. CT scan has been used in the evaluation of tuberculous meningitis to identify complications like hydrocephalus etc and to know about the prognosis. [5] In adolescents and adults with tuberculous meningitis and hydrocephalus, the signs of increased intracranial pressure and drowsiness are more predominant. Such patients are usually benefited by a shunt. The timing of the ventriculo peritoneal shunt procedure and cerebral complications has an effect on the final outcome. Early VPS give better outcome. [6] Tuberculosis meningitis is a major health problem and in Pakistan is associated commonly with hydrocephalus, which is treated-by ventriculo-peritoneal shunting. [7]

Cerebrospinal fluid diversion procedures in the form of shunt or external ventricular drain are indicated in patients with hydrocephalus after tuberculous meningitis. [8] When hydrocephalus is the presenting feature, urgent neurosurgical decompression may be required as mortality is related to the severity of hydrocephalus.[9]

This study was conducted in the Department of Neurosurgery Jinnah Post Graduate Medical Centre, Karachi to know about the outcome in terms of mortality, in patients with post tuberculous meningitic

hydrocephalus after neurosurgical intervention.

Patients and Methods

This study was conducted in the Department of Neurosurgery, Jinnah Post Graduate Medical Centre, Karachi. It was a one year study and total fortytwo patients were included. We included all adult patients with hydrocephalus secondary to tuberculous meningitis. We excluded patients below 15 years of age, those who were managed conservatively and those who had already been operated somewhere else and later on shifted to our department.

The data were collected with the help of a proforma, including the clinical features, investigations and information about the surgical intervention and outcome of the patients. All the patients with tuberculous meningitis and hydrocephalus, included in this study were put on anti tuberculous treatment. They were divided into four grades according to the Glasgow coma scale i.e. Grade I with GCS 15 and no deficit, grade II with GCS 15 but with neurodeficit, grade III with GCS 9-14 and grade IV with GCS 3-8. For outcome they were divided into two groups. Grade 1-3 were included in group I and grade four were included in group II. Their diagnosis was made on clinical basis and CSF findings. In all patients CT scan brain was done showing hydrocephalus and the radiological evidence of tuberculous meningitis. The decision for neurosurgical intervention with VP shunt or external ventricular drain made according to general condition and conscious level of the patients. In patients with clear CSF and afebrile condition, VP shunt was inserted but in patients with temperature and with CSF not clear, external ventricular drain (EVD) was inserted. In 27 patients of group I, VP shunt was inserted while in two patients initially EVD was inserted followed by VP shunt when CSF became clear. In 11 patients of group I, first EVD was inserted and when the CSF became clear and the condition of the patient improved then VP shunt was inserted and in 2 patents of group II VP shunt was inserted initially. These patients were observed for mortality after surgical intervention.

Results

Total patients studied for post tuberculous meningitic hydrocephalus were 42. Out of them, 25 (60%) were males and 17 (40%) were females. These patients were divided into different age groups. The age range was from 15 to 60 years. Twenty two patients were below the age of 30 years, and four patients had age above 50 years. (Figure I.)

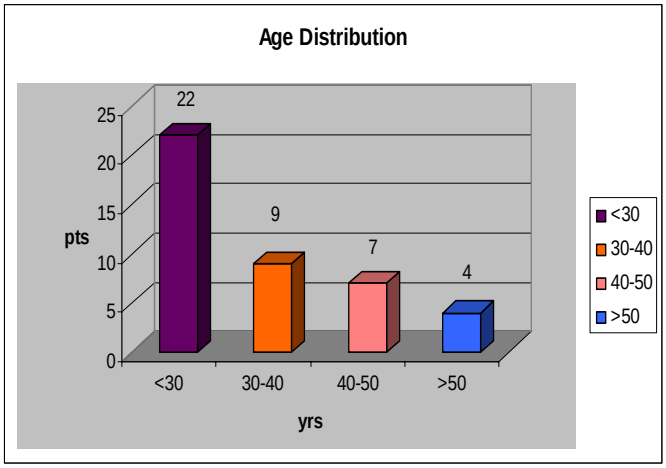

Figure I: Age distribution of patients with post tuberculous meningitic hydrocephalus.(n=42)

Table I: Outcome of neurosurgical intervention in patients with post meningitic hydrocephalus. (n=42)

Intervention and outcome	Group I n=29	Group II n=13	Impro-ved	Mort -ality
VPshunt inserted	27	2	27	2
EVD inserted	2	11	7	6
Improved	27	7	34	-
Mortality	2	6	-	8

All of these patients presented with history of fever and drowsiness. Fifteen patients had family history of tuberculosis while twenty seven patients had past history of tuberculosis. Clinically thirty one patients were febrile while twenty six patients had neck rigidity.

These patients were divided into two groups according to the GCS. Twenty nine patients with GCS 9-15, were included in group I and 13 patients with GCS 3-8 were included in group II. CSF examination was done in all of these patients. Protein level was more than 100 mg/dl in 18 patients while it was less than 100 mg/dl in 24 patients. Neutrophil level was more than 5 cell/ dl in nine patients and it was less than 5 cell / dl in 33 patients. Lymphocytes were more than 100/ dl in 11 patients while less than 100/dl in 31 patients.

Neurosurgical intervention employed was either EVD or VP shunt. When the patient was febrile and CSF not clear EVD was inserted but when the CSF was clear and patient afebrile VP shunt was inserted. We put VP shunts in 29 patients, two of them were from group II,

and only two patients expired, one of group I and one of group II. While EVD was inserted in 13 patients, 2 of them were in group I. In five patients when they improved and CSF became clear EVDs were replaced with VP shunts while six patients expired out these eleven patients. So from group I there were 2 (6.9%) expiries and from group II there were 6 (46.15%) expiries as shown in table I. The overall mortality in 42 patients was 19%.

Discussion

One of the most common complications of tuberculous meningitis is hydrocephalus of the communicating type, which is due to the formation of thick gelatinous basal exudates around the interpeduncular and pontine cisterns in the acute stages and adhesive leptomeningitis in the chronic stages. [10] According to one study [11] in which there were total 32 patients, they divided their patients into two groups, above 12 years of age and below 12 years with average age of 23 years. In the present study there are 42 patients and all the patients are above the age of 15 years. The average age is 35.6 years. One study shows average age 50.3 years. [1] In tuberculous meningitis there is fever due to infection and involvement of the meninges leads to meningeal irritation which causes neck rigidity. Fever is 44% and neck rigidity is 33% in patients with post tuberculous meningitic hydrocephalus. Another study [12] shows 75% neck rigidity. In our study out of 42 patients, 31 presented with history of fever while 26 patients had neck rigidity. When these patients are put on steroids and ATT, their fever and neck rigidity are controlled, so we put all of them on ATT and steroids. GCS is very important because we can determine the outcome of patients. Low GCS means poor prognosis and high GCS leads to good prognosis. There are four grades of the post tuberculous patients with hydrocephalus based on the GCS as grade III with GCS 9-14 and grade IV with GCS 3-8 (13), but we divided our patients into two groups as group I with GCS 9-15 and group II with GCS 3-8.

CSF examination is very important in these patients with tuberculous meningitis. When the cell count is more specially neutrophils and when protein is high then we can not go for VP shunt insertion because high protein leads to shunt blockage and high cell count leads to shunt infection. According to one study [13] the CSF examination was based on protein less than 50mg/dl and more than 50 mg/dl and total cell count less than 50/mm3 and more than 50/mm3. In our study in 18 patients the protein concentration was more than 100mg/dl while in 24 patients it was less than 100 mg/dl. In 33 patients the neutrophils were less than 5/mm3 while in 9 patients it was more than 5/mm3. Similarly the lymphocyte count was more than 100/mm3 in 11 patients and less than 100/mm3 in 31 patients. CT scan plays a very important role in the diagnosis and management of post tuberculous meningitic hydrocephalus and should be undertaken in initial investigations to provide a baseline information and to know about the complications especially hydrocephalus. [14]

When neurosurgical intervention is required for post tuberculous meningitic hydrocephalus, we go for either VP shunt or EVD. Choice of intervention is based on the condition of the patient, CSF examination and temperature. Early shunting still remains the best option to prevent long-term neurological sequelae. [15] According to one study, [16] there were 30 patients, five in GCS 3-7 were inserted EVD and 3 of them died and in remaining patients, VP shunt was inserted. The overall mortality was 22% but in our study the mortality rate is 19%. according to another study, [9] all patients in Grade IV should undergo external ventricular drainage and only those who show a significant change in their neurological status within 24 to 48 hours of drainage, should have shunt surgery. In that study all patients in grade IV were inserted EVD and all of them died. In our study out of 13 patients in grade IV, only six died and the mortality of grade IV patients was 46.15%.

The management of tuberculous meningitis with hydrocephalus is complex. In most centers advocating ventriculoperitoneal shunting only in the presence of raised CSF pressure during the early phase of tuberculous meningitis with hydrocephalus, a combined multi-disciplinary approach will help to prevent neuronal injury due to progressive ventricular enlargement and inflammation. [16,17] Ventricular drainage should be done early when hydrocephalus is diagnosed in patients with tuberculous meningitis as early intervention leads to good prognosis. [18]

Conclusion

Tuberculous meningitis with hydrocephalus is a very serious illness. When neurosurgical intervention is needed, it should be done in time. When the CSF is clear, patient is afebrile and general condition of the patient is good, VP shunt should be inserted in time but when CSF is not clear, patient is febrile and general condition or the patient is not well, EVD should be inserted which can be changed into VP shunt once the CSF becomes clear and patient's condition improves. Mortality rate is low when the GCS is above 8 and it is high when the GCS is below 8/15.

References

1. Chan K.H, Cheung R.T.F, Fong C.Y, Tsang K.L, Mak W, and Ho S.L. Clinical relevance of hydrocephalus as a presenting feature of tuberculous meningitis. Q J Med 2003; 96: 643-648.

2. Chan KH, Ho PL, Cheung RTF, Tsang KL, Fong CY, Ho SL. Tuberculous meningitis with tuberculomata presenting as postpartum pyrexia of unknown origin. Hosp Med 2003.
3. Goel A. Tuberculous meningitis and hydrocephalus. Neurol India 2004; 52:155.
4. Humphries M.The management of tuberculous meningitis. Thorax. 1992; 47: 577–581.
5. Srikanth S G, Taly A B, Nagarajan K, Jayakumar, Patil P N S. Clinicoradiological features of tuberculous meningitis in patients over 50 years of age. J Neurol Neurosurg Psychiatry. 2007; 78:536-38.
6. Kemaloglu S, Özkan U, Bukte Y, Ceviz A, Özates M. Timing of Shunt Surgery in Childhood Tuberculous Meningitis with Hydrocephalus. Pediatric Neurosurgery 2002; 37:194-198.
7. Shams S, Ayesha M, Sallahuddin S, Majeed S. Tuberculous meningitis; role of up shunting.Professional Med J 2001; 8:526-29.
8. Jonathan A, Rajshekhar V. Endoscopic third ventriculostomy for chronic hydrocephalus after tuberculous meningitis. Surgical Neurology 2005; 63: 32 – 35.
9. Palur R, Rajshekhar V, Chandy MJ, Joseph T, Abraham J. Shunt surgery for hydrocephalus in tuberculous meningitis: a long term follow-up study. J Neurosurg 1991; 74:64–69.
10. 10 Tandon PN,Pathak SN. Tuberculousis of the centeral nervous system. In: spillane LW,ed. Tropical neurology.london oxford university press. 1973: 37-51.
11. Husain M, Jha DK, Rastogi M, Husain N, Gupta RK. Role of neuroendoscopy in the management of patients with tuberculous meningitic hydrocephalus. Neurosurg Rev. 2005; 28:278-83.
12. Ahmadinejad Z, Ziaee V, Aghsaeifar M & Reiskarami SR: The Prognostic Factors Of Tuberculous Meningitis: The Internet Journal of Infectious Diseases. 2003; 3: 212-15.
13. Mathew JM, rajshekhar V, chandy MJ. Shunt surgrey in poor drag patient tuberculous meningitis and hydrocephalus.effect of response to external ventricular drainage and other variables on long term outcome. j neurol, neurosurgery , psychiatry. 1998; 65: 115-118.
14. Kingsley DP, Hendrickse WA, Kendall BE, Swash M, Singh V. Tuberculous meningitis: role of CT in management and prognosis. J Neurol Neurosurg Psychiatry. 1987; 50:30-36.
15. Sil K, Chatterjee S, Shunting in tuberculous meningitis: a neurosurgeon's nightmare. Childs Nerv Syst. 2008; 24:1029-32.
16. Irfan A, Qureshi A. Role of ventriculoperitoneal shunt in post-tuberculous meningitic hydrocephalous. J Pak Med Assoc. 1995; 45: 37-38.
17. Aliyu S H, Ganesan D, Enoch D A, Watts C, Lever A M L. Tuberculous meningitis and hydrocephalus treated successfully with a combination of immunomodulation and cerebrospinal fluid diversion. Infect Dis J Jan - Mar 2007; 16:22-24.
18. Newman PK, Cumming WJ, Foster JB. Hydrocephalus and tuberculous meningitis in adults. J Neurol Neurosurg Psychiatry. 1980; 43: 188-90.